

CASE STUDY

Use of Electromagnetic Navigation Bronchoscopy® for Insertion and Fixation of Radiosurgical Markers for the Setup and Tracking of a Lung Tumor During Radiation Therapy

Joseph Cicensia, M.D.
Saint Vincent's Cancer Center

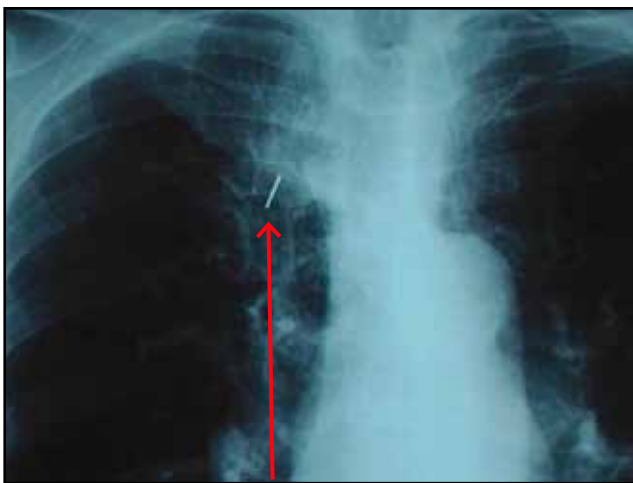
Introduction:

With the recent advances in the precision of treatment delivery, radiation therapy has become more accurate, integrating high-resolution real-time imaging with radiation delivery for the treatment of lung cancer. A recent development in this field, Image-Guided Radiation Therapy (IGRT) with real-time tumor tracking, promises to improve efficacy and reduce morbidity. This technique can be enhanced by implanting radio-opaque markers; however the marker insertion technique has not yet been widely established.

Case Report:

A 71-year-old female with severe emphysema was evaluated in our clinic for treatment of recurrent

non-small cell lung cancer. She was initially diagnosed with primary adenocarcinoma of the lung by fine needle aspiration of a mass in the right upper lobe, posterior segment. She was deemed inoperable due to her emphysema, and was treated with standard-dose radiotherapy (50 Gray), with reduction in tumor size and FDG uptake. A repeat chest radiograph nine months later, however, revealed an interval increase in the size of the tumor. A PET scan also revealed a return of FDG activity (SUVmax 7.6). She refused chemotherapy, and high-dose stereotactic radiotherapy was planned. To track the changes in tumor position during the treatment, radiosurgical markers were inserted into the tumor using electromagnetic navigation bronchoscopy.



Fiducial marker

Discussion:

Total radiation delivered to a tumor is limited by its toxicity to surrounding normal lung tissue. Problems in targeting radiotherapy include changes in tumor position, which can be due to the normal respiratory cycle and unpredictable baseline shifts in respiratory rates and amplitude.

Radiosurgical markers inserted into or near the lung tumor are useful both for daily setup as well as real-time tumor tracking of the tumor position. These markers can be inserted into or near the tumor using a transthoracic needle or conventional bronchoscopy. The former is associated with a high frequency of pneumothorax and the latter with marker migration or inaccurate placement.

To minimize complications and enhance accurate placement, the superDimension® Electromagnetic Navigation Bronchoscopy® System can be utilized. It allows for real-time accurate and minimally invasive navigation to anywhere within the lungs using combined CT-image and electromagnetic guidance. Using this modality, a working

channel can be guided bronchoscopically to a lung tumor; through this channel, radiosurgical markers can be placed using a TBNA needle. Once the radiosurgical markers are placed, real-time tumor tracking can be achieved during radiotherapy planning and delivery.

Radiotherapy planning is done using a three-dimensional CT-based planning system. At the time of radiotherapy, this radiosurgical marker is used to position the patient accurately within the radiation field by superimposing the planning CT on a real-time fluoroscopic image generated by the system. In addition, utilizing respiratory gating software, the marker is also used to assess the effect of respiratory motion, allowing radiation to be delivered during one phase of ventilation. With this confirmation of accuracy, higher doses of radiation can be delivered to target sites by reducing the margins of delivery around the tumor. This serves to avoid damage to the healthy adjacent tissue, allowing for increased total doses of radiation to be delivered to the tumor.

Conclusion:

It is important to balance the safety of the implantation and the benefits to be derived from the radiosurgical markers with respect to localization. With the use of advanced radiotherapy systems, this balance favors the use of a marker, provided the invasiveness of implantation is acceptable. In our experience, the superDimension Electromagnetic Navigation Bronchoscopy System greatly improves the safety and accuracy for insertion of these markers.

Joseph Cicens, M.D.

superDimension®

United States Office

superDimension, Inc.
161 Cheshire Lane, Suite 100
Minneapolis, MN 55441-5433
U.S.A.

Tel: +1-763-210-4000
Toll Free: +1-800-387-9016
Fax: +1-866-706-9639
info.us@superdimension.com