

# CASE STUDY

## superDimension® Electromagnetic Guided Navigation Enables Accurate Positioning of Fiducial Markers within Peripheral Nodules, Allowing for Early Treatment of Lung Cancer by Radiation Therapy – Patient 1

Alan Forbes, M.D., Juan J. Herran, M.D.  
M.D. Anderson Cancer Center Orlando

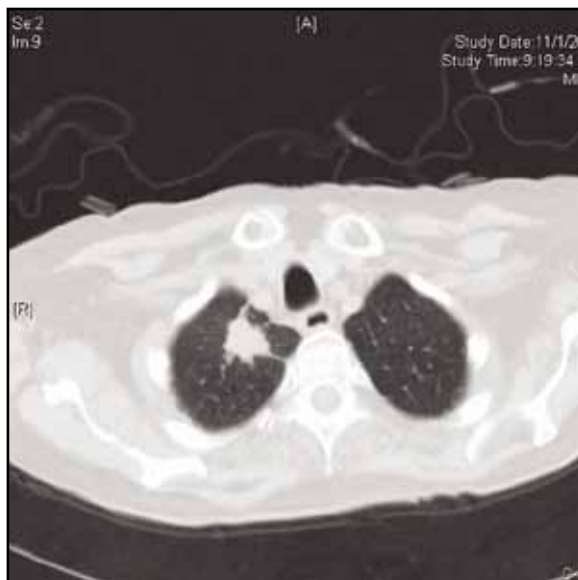
### Introduction:

One of the promising methods for early treatment of lung cancer embraces the use of radiation therapy. To make the most of this technology, radiosurgical markers (fiducial markers) need to be accurately positioned at the desired location of treatment.

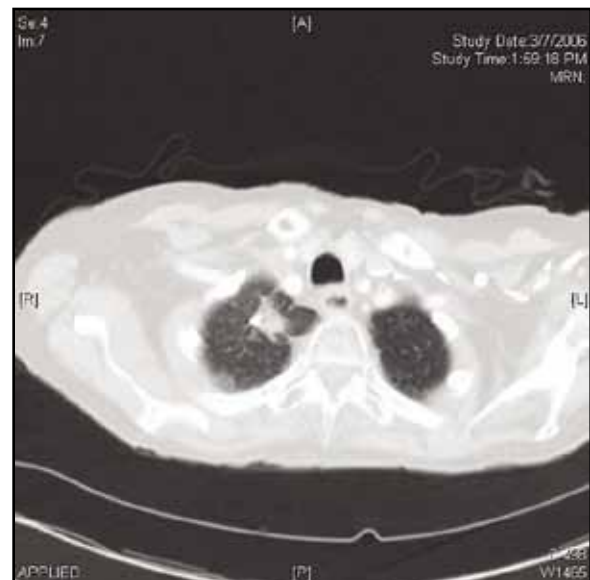
### Case Report:

A 75-year-old female, current smoker (2 pks/day) with a medical history of coronary artery disease, diabetes mellitus and hypertension. The patient had a cerebrovascular accident in 1998. She is noted to have obstruction of the carotid arteries. She has had coronary artery angioplasty with placement of four stents.

The routine chest X-ray detected a mass and a following chest CT showed a 20 x 15 mm right apical mass in the right lung apex with no mediastinal or hilar adenopathy. PET scan revealed a single round area of hypermetabolism corresponding to the mass seen on the CT scan. Following FNA, the diagnosis was T1N0M0, stage IA non-small cell lung carcinoma. Due to the patient's co-morbidities, surgery was excluded and it was decided to treat her with radiation therapy after placing radiosurgical markers at the treatment location.



Pre-treatment CT



Post-treatment CT

Continued on reverse

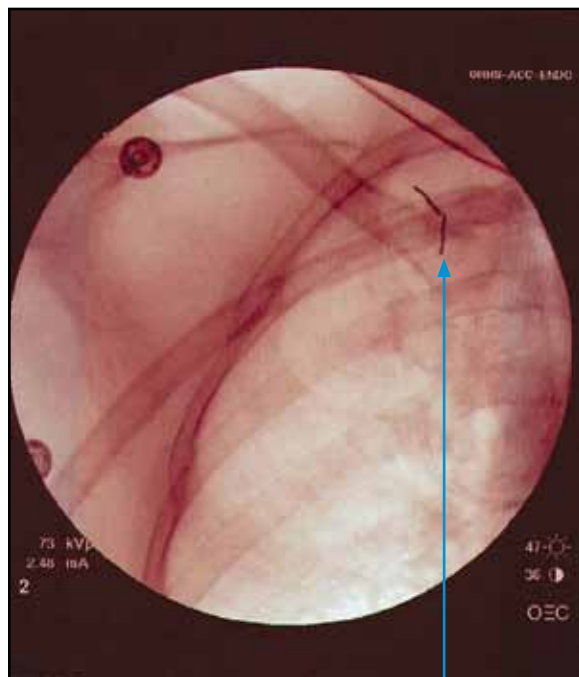
Prior to the procedure, a BARD MW-319 double lumen needle was loaded with a 10 mm Visicoil™ marker. superDimension® electromagnetic navigation was used to place an Extended Working Channel (EWC) Catheter all the way to the peripheral nodule. Next, the lumen needle was pushed within the EWC to the nodule and under fluoroscopy guidance, the inner lumen was extracted, leaving the Visicoil at the desired treatment location. Subsequently, the patient started receiving radiotherapy treatments.

Thoracic CT scan, performed one month after treatment, revealed a slight decrease in the size of the RUL mass to 17 mm that still has a spiculated appearance.

### Conclusion:

superDimension Electromagnetic Navigation Bronchoscopy® System can be applied to accurately position radiosurgical markers within peripheral small nodules. This allows for early treatment of lung cancer and it is commonly known that early therapy of lung cancer substantially decreases mortality rates.

Alan Forbes, M.D., Juan J. Herran, M.D.



Fiducial markers

**superDimension®**

**United States Office**

superDimension, Inc.

161 Cheshire Lane, Suite 100

Minneapolis, MN 55441-5433

U.S.A.

Tel: +1-763-210-4000

Toll Free: +1-800-387-9016

Fax: +1-866-706-9639

[info.us@superdimension.com](mailto:info.us@superdimension.com)